

# Detection of cerebral ischaemia using transfer learning techniques

1<sup>st</sup> Cristina Antón-Munárriz  
Radiology area  
Hospital Universitario de Navarra  
Pamplona, Spain  
crian2345@gmail.com

2<sup>nd</sup> Rafael Pastor-Vargas  
Computer Science Faculty  
UNED  
Madrid, Spain  
rpastor@scc.uned.es

3<sup>rd</sup> Juan M. Haut  
School of Technology  
University of Extremadura  
Cáceres, Spain  
juanmariahaut@unex.es

4<sup>th</sup> Antonio Robles-Gómez  
Computer Science Faculty  
UNED  
Madrid, Spain  
arobles@scc.uned.es

5<sup>th</sup> Mercedes E. Paoletti,  
University Centre of Merida  
University of Extremadura  
Mérida, Spain  
mpaoletti@unex.es

6<sup>th</sup> José Alberto Benítez-Andrades  
Dept. of Electric, Systems and Automatics Engineering  
Universidad de León  
León, Spain  
jbena@unileon.es

**Abstract**—Cerebrovascular accident (CVA) or stroke is one of the main causes of mortality and morbidity today, causing permanent disabilities. Its early detection helps reduce its effects and its mortality: time is brain. Currently, non-contrast computed tomography (NCCT) continues to be the first-line diagnostic method in stroke emergencies because it is a fast, available, and cost-effective technique that makes it possible to rule out haemorrhage and focus attention on the ischemic origin, that is, due to obstruction to arterial flow. NCCT are quantified using a scoring system called ASPECTS (Alberta Stroke Program Early Computed Tomography Score) according to the affected brain structures. This paper aims to detect in an initial phase those CTs of patients with stroke symptoms that present early alterations in CT density using a binary classifier of CTs without and with stroke, to alert the doctor of their existence. For this, several well-known neural network architectures are implemented in the ImageNet challenges (VGG, NasNet, ResNet and DenseNet), with 3D images, covering the entire brain volume. The training results of these networks are exposed, in which different parameters are tested to obtain maximum performance, which is achieved with a DenseNet3D network that achieves an accuracy of 98% in the training set and 95% in the test set.

**Index Terms**—Cerebral Ischaemia, Computed tomography, Deep Learning, Transfer Learning, Ictus Dataset

## I. INTRODUCTION

Stroke is the obstruction by a thrombus or embolus of a cerebral artery that causes a lack of blood supply to the territory irrigated by the vessel and, consequently, cellular ischaemia, which may be reversible in the first few hours. However, if the cause persists, neuronal death or infarction occurs, which is irrecoverable. The most frequent location of ischaemic stroke is the anterior circulation. The internal carotid arteries and anterior cerebral arteries (ACA), and middle cerebral arteries (MCA) belong to this territory. Occlusion of the MCA is the most common. Its treatment (intravenous thrombolysis) should be performed during the first 4-6 hours

Special thanks to Hospital Universitario de Navarra for letting authors collect data needed to build the Ictus Dataset

after the initial symptom because, at later times, haemorrhagic complications increase [1], [2] and irreversible neuronal death occurs.

The *Alberta Stroke Program Early Computed Tomography Score* (ASPECTS) was described by Barber et al. [3] and was designed to assess early signs of ischaemia in the anterior circulation with non-contrast CT. The ASPECTS is a 0-10 scale on which points are deducted if computed tomography (CT) hypodensity is observed in specific regions of the MCA-supplied territory (6 cortical areas, insula, caudate, lenticular and internal capsule) shown in the figure 1. A score of 10 implies a normal study, and a score of 0, diffuse involvement of the entire territory supplied by the anterior circulation. A score of 7 or lower predicts more haemorrhagic risk and a worse prognosis. The presence of hypodensity affecting more than one-third of the MCA territory is a contraindication for thrombolytic therapy.

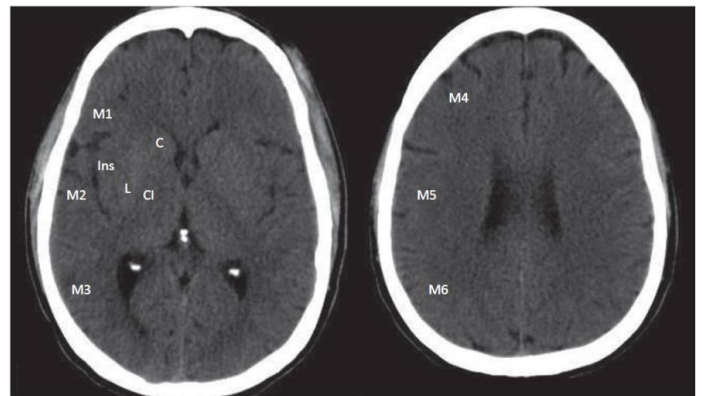


Fig. 1. Areas assessed in the Alberta Stroke Program Early CT Score (ASPECTS). Six cortical areas (M1, M2, M3, M4, M5 and M6), insula (I), caudate (C), lenticular (L) and internal capsule (CL).

The assessment of these hypodensities on an NCCT can

be challenging to diagnose as they are very faint, and their detection is highly dependent on the observer and their experience. That is why machine learning and, more specifically, deep learning for image classification can greatly help in their detection and help the radiologist to perform a detailed search of specific areas of the brain where the algorithm has detected the possible presence of infarction.

The application of Machine Learning (ML) and especially Deep Learning (DL) techniques to medical images allows the automatic extraction of non-trivial and non-linear features from image data and constitutes a very broad field of research with more and more researchers involved and the emergence of more and more applications for disease diagnosis.

Medical images are inherently three-dimensional, so using neural networks with 3D filters is natural, although they require a higher computational cost than 2D ones. In addition, advances in parallel and distributed computing, deep learning algorithms, and the emergence of powerful GPUs have made the increasingly extensive use of 3D models for medical image segmentation and classification studies possible. [1]

In the case of stroke, there are already studies and also some certified applications, such as e-ASPECTS, of private property, which use supervised automatic learning using machine learning techniques for the analysis of stroke with NCCT, based fundamentally on random forest algorithms, manual segmentation by the radiologist, and using methods for comparing the healthy cerebral hemisphere with the diseased one [4]–[6]. However, the use of deep neural networks has yet to be considered so far and is the subject of study in this paper. Section II will show some applications of deep learning neural networks in different medical imaging domains and how DL has become a fundamental tool for decision-making. Section III will briefly present the data used to develop the neural network training experiments. At the same time, Section IV will show the network design decisions (based on transfer learning techniques) and the results obtained. Finally, section V will show the conclusions obtained.

## II. DEEP LEARNING AND MEDICAL IMAGES

Since the definition of the ANN (Artificial Neural Network) concept, which was first introduced in 1943 by McCulloch and Pitt [7], this area of artificial intelligence has evolved very rapidly (especially in recent years). McCulloch and Pitt presented a mathematical model of artificial neural networks based on the fact that neurons operated on binary impulses and formulated it as a threshold step function. A neural network provides a method to obtain non-linear models by using the neurons in the hidden layer (which use a non-linear activation function). This non-linearity allows for capturing features and patterns in the data used for training that would not be possible with more traditional algorithms. One particular type of deep neural networks are called Convolutional Neural Networks (CNN), [8]. They are used intensively in image data domains, such as medical imaging. These networks have evolved rapidly, specifically for their different application domains. Parallel to all this improvement in deep learning for

computer vision in image classification, advances in biological and medical technologies have made it possible to obtain and store large amounts of medical images, which we can classify and test on different CNNs architectures for feature extraction and pattern retrieval. Many proven applications in medicine and biology have used CNNs for image classification and segmentation, like in our case. They cover a very wide range of problems, from cancer screening and disease monitoring to suggesting personalised treatments and disease diagnosis. Moreover, the origin of the data is very varied: X-rays, computed tomography, magnetic resonance imaging, retinography, pathological anatomy extensions, human genome sequences, etc. [9].

The following are just a few applications that use medical imaging with CNN construction, which give an idea of the extensive field of research that is underway, which can be applied to the classification of any disease, in any imaging technique and with the use of a wide variety of convolutional network architectures.

In the classification, detection and segmentation of lung nodules in CT, deep learning techniques have been used with 2D and 3D convolutional networks, with different network architectures, many of them with autoencoder construction, achieving a diagnostic accuracy between 84-95% [10]–[17].

MICCAI-BRATS (Brain Tumor Segmentation Challenge) holds annual brain tumour segmentation challenges. Its website [18] publishes the winners of these challenges and their results, primarily using data from Magnetic Resonance Imaging (MRI) [19]–[21] studies. One of these studies proposes a 3D DenseNet neural network for predicting the IDH genotype (related to prognosis and response to treatment) of gliomas, achieving an accuracy of 84.6

2D and 3D CNNs have also been used for Alzheimer's disease classification with MR imaging [22]–[24].

ISLES (*Ischemic Stroke Lesion Segmentation*) proposes challenges for ischemic brain lesion segmentation. Most of them are currently performed on [25] MR images. On their website [26], we can see the latest challenges that have been proposed. The scientific papers currently published on machine learning in the diagnosis of acute cerebral ischaemic lesions in NCCT are based on techniques that analyse the symmetry between brain hemispheres [4], [27], [28] or perform segmentation with generative networks in contrast-enhanced CT studies [29] and the least use 2D [30] and 3D [1] CNNs.

In the case of stroke, some works use different artificial intelligence algorithms for stroke classification, segmentation and diagnosis on NCCT and AngiographyCT images [4] [5] [6]. Mokli et al. [31] present a review of commercially available applications using automatic and semi-automatic algorithms for image analysis to diagnose acute cerebral infarction. However, there is very little specific information on the technical details of the algorithms or details on training and validation data available in the general information on the applications' websites [32].

Currently, five software platforms integrate machine learning algorithms for ictus detection: Brainomix e-ASPECTS

(Oxford, UK), Olea Medical (La Cio-tat, France), Siemens Frontier (Erlangen Germany), iSchemaView RAPID (Rapid Perfusion and Diffusion Processing, California, USA) and Viz.ai (California, USA). [33].

The Viz.ai platform is based on head and neck CT angiography analysis using a convolutional neural network artificial intelligence platform to identify occlusion of large anterior circulation vessels. [34].

The e-ASPECTS and RAPID ASPECTS platforms are certified for clinical use and perform stroke diagnosis and segmentation in NCCT. Of the two, e-ASPECTS has the most validation studies, performing similarly to expert radiologists. [31]. Medical software falls under the category of medical devices. They are validated by the US FDA (Food and Drug Administration) and MRD (Medical Device Regulation) in the EU. These bodies are the ones that certify software products.

Frontier ASPECTS, is not certified at the time of writing. [35]. Studies are comparing the performance of e-ASPECTS and Frontier, with the former performing highly and the latter moderately in agreement with the experts with whom they are compared [36].

E-ASPECTS and RAPID ASPECTS aim to quantitatively assess focal ischaemic damage using the ASPECTS score. They contain the complete cranial CT in DICOM format and visually highlight the affected region with heat maps. The difference lies in the machine learning methods they use. Brainomix first classifies and then segments using Random forest learning throughout its procedure. RAPID ASPECTS does skull and cerebrospinal fluid removal, apply atlases to construct the 20 regions of the ASPECTS score (ten in each cerebral hemisphere) and classifies and segments using Random forest learning.

It follows from the above that the algorithms used by these applications are either not public or do not use neural network techniques. Therefore, the aim of this article is to provide a CCN network model that radiologists can use for assisted decision-making. A concrete Dataset is needed to achieve this goal, which will be presented in the next section.

### III. ICTUS DATASET

In the design of AI algorithms, it is necessary to have data, usually already labelled (with or without Ictus, in this case). As a first step, it is necessary to check if there are specific datasets that can be used for the purpose of the paper. A search for possible datasets in the field of stroke detection was carried out, and two possible sources were found. As a reference source, the website [37] was used. On this site, there is an extensive collection of challenges that have been organised in the area of medical imaging. Two possible datasets were found. The first consists of segmentation of cerebral infarction in CT Angiography and magnetic resonance images launched by ISLES [26] in 2018, and the second one of intracranial haemorrhage in non-contrast CT images proposed in Kaggle [38] in 2019. None of these sources was valid for the proposed objective (automated stroke detection), so it was decided to build a specific dataset. To construct the dataset, it is necessary

to understand the structure and format of the images acquired by CT.

#### A. Computed Tomography (CT) and Hounsfield Units (HU)

To train the neural networks, it is necessary to have a data set (Dataset) containing the 3D images. These images correspond to the cranial CT scans and the transformation of the measurement of the radiation intensity of these scans (which may vary according to the measuring equipment used) into "Hounsfield" units or attenuation coefficient numbers. These units allow the elaboration of a density scale applicable to any image obtained with any equipment. To elaborate the scale, the attenuation produced by water under average temperature and pressure conditions on a beam of rays was taken as a reference and attributed a value of zero (0 HU). The attenuation value of air under the same conditions is defined as -1000 HU, extending up to +1000 for dense, attenuated tissue. These values allow a grey scale for HU representation and, thus, the creation of 3D and 2D images (axial slices of the 3D image). The structure of the 3D image and the corresponding 2D images are shown in the figure 2.

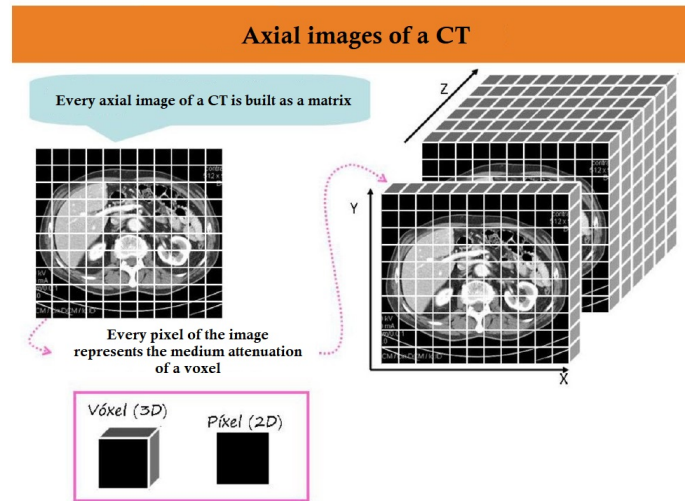


Fig. 2. Features of a CT image.

#### B. Dataset features and description

Obtaining the set of cranial CT data labelled with and without stroke has been a slow and complex task, requiring several steps. Imaging studies of any diagnostic modality, be it tomography, ultrasound, MRI, retinography, etc., are usually in DICOM format [39]. This format is the standard for the exchange and representation of medical images and contains not only the image but also the patient's personal data, his or her history number and other data referring to the machine and place where it was taken. In order to comply with the data protection law, the corresponding authorisation was requested from those responsible for the digital imaging section of the hospital to be able to store the CT studies in DICOM format.

Once this consent was obtained, access was provided to the software necessary to obtain the CT studies anonymously.

The dataset of non-contrast CTs in DICOM format contains images of hospital patients from June 2015 to September 2020, in which the stroke code is activated. Studies with haemorrhage or other pathologies that cannot be classified as ischaemic stroke are discarded. The studies are classified by radiologists as normal or with signs of stroke. The data were divided into two groups: group 0, with stroke, and group 1, without stroke. All patients in group 0 had some degree of ischaemic involvement in the MCA territory, either due to direct obstruction of the MCA by thrombus or embolus or secondary to obstruction of the ipsilateral carotid artery had some territory with hypodensity in CT according to the ASPECTS classification. The data includes patient identification, whether the patient belongs to group 0 or 1, affected regions, ASPECTS score and affected cerebral hemisphere. Finally, anonymised images are obtained in DICOM format and stored in a secure cloud environment, on Google Cloud Storage. The images are acquired with a thickness of 3mm in multidetector CT equipment of 64 crowns. Some older isolated studies are acquired on a helical CT with 5 mm slices.

In total, a dataset of 264 cases with stroke and 264 cases without stroke has been created. Each case corresponds to a 3D image which can be divided into 2D axial slices. Each image has a sufficient diagnostic resolution ( $256 \times 256 \times 80$  pixels).

#### IV. RESULTS

As seen in the previous section, the data set that could be constructed is limited (512 images), and therefore, it was foreseeable that the results obtained with non-pre-trained neural networks would not be significant in terms of accuracy obtained in training and validation/testing. In fact, training with various proposed Convolutional Neural Networks structures did not give reliable results (accuracies below 60%).

Thus, it was decided to employ transfer learning techniques [40] with already pre-trained networks, especially those using 3D structures in a known way (in other fields of medical image detection). The following pre-trained CNN were selected: VGG, ResNet, DenseNet and NasNet.

The metrics used to assess the performance of our networks are the accuracy and confusion matrix, standard measures for evaluating the performance of any classifier. From this matrix, we can also obtain other data that provide us with more precise information, such as precision and sensitivity. We can use either of the two metrics, sensitivity and precision. However, depending on the problem we are considering, we may be interested in minimising false positive cases, in which case we would use precision, or on the other hand, we may be interested in reducing false negative cases, in which case we would use sensitivity. In this specific case of stroke detection, it is very important to minimise false negatives which correspond to an incorrect stroke diagnosis. In other words, we must pay special attention to sensitivity. Unfortunately, improving on both metrics simultaneously is impossible, as increasing sensitivity reduces accuracy and vice-versa. From the confusion matrix, we can obtain two other metrics, which are the specificity and the so-called F1-score, i.e. the weighted harmonic mean of accuracy and sensitivity.

In the first training tests with the Ictus dataset, the VGG and NasNet networks were discarded due to their excessive memory requirements. This requirement is essential for the possibility of incorporating the inference model into the radiologist's decision support software. Thus, the DenseNet and ResNet networks were selected.

The table I show the accuracy data obtained as well as the rest of the metrics used to compare the trained models. It can be seen in the tables that in the case of the DenseNet structure, the best result is obtained in the interaction/version 2.2 with an accuracy of in the training part of 98% and in the test part of 95%. There is no overfitting of the network, the network has

DenseNet3D										
Version	Optimizer	Learning Rate	Loss Function	Accuracy		Confusion matrix				Batch Size
				Train	Test	Sensibility	Specificity	Precision	F1-Score	
1.0	SGD	0.001	Bin-ce	100%	40%	-	-	-	-	1
1.1	Adam	0.001	Bin-ce	100%	50%	-	-	-	-	1
1.1.1	Adam	0.001	Bin-ce	98%	78%	80%	75%	77%	0.78	2
1.2	SGD	0.001	Cat-ce	100%	36%	-	-	-	-	1
1.2.1	SGD	0.001	Cat-ce	100%	94%	95%	93%	93%	0.93	2
1.3	Adam	0.001	Cat-ce	99%	82%	88%	75%	79%	0.82	2
2.0	SGD	0.01	Cat-ce	95%	80%	64%	96%	95%	0.76	15
2.1	SGD	0.001	Cat-ce	97%	87%	77%	98%	96%	0.85	15
2.2	SGD	0.001/0.0001 epoch=80	Cat-ce	98%	95%	95%	96%	96%	0.95	15
2.3	SGD	0.001/0.0001 epoch=30	Cat-ce	96%	91%	90%	92%	92%	0.90	15
2.4	SGD	0.001/0.0001 epoch=20	Cat-ce	97%	92%	93%	91%	91%	0.91	15
ResNet3D										
Version	Optimizer	Learning Rate	Loss Function	Accuracy		Confusion matrix				Batch Size
				Train	Test	Sensibility	Specificity	Precision	F1-Score	
1.0	Adam	0.001	Cat-ce	95%	68%	69%	68%	69%	0.68	1
1.1	Adam	0.001	Cat-ce	87%	71%	68%	74%	73%	0.68	2
2.0	Adam	0.001	Cat-ce	95%	79%	75%	83%	82%	0.78	10
2.1	SGD	0.001	Cat-ce	100%	76%	77%	77%	78%	0.77	10

TABLE I  
DENSENET3D AND RESNET3D, TRAINING AND EVALUATION WITH SEVERAL HYPERPARAMETERS

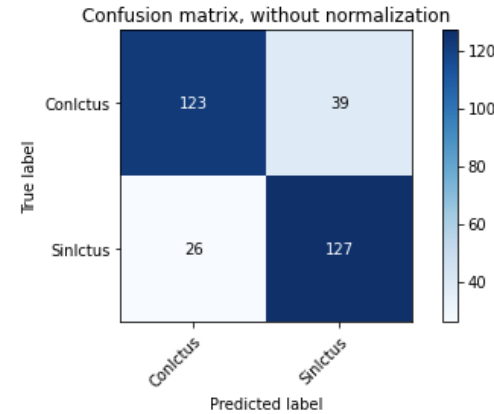
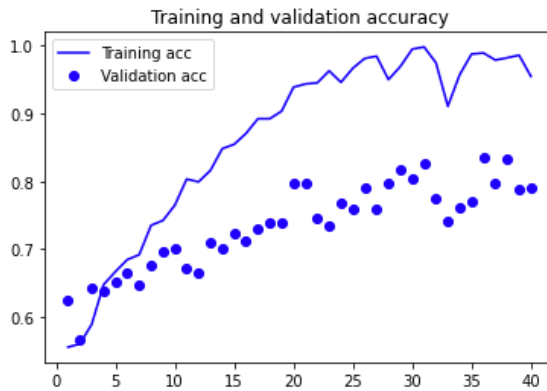
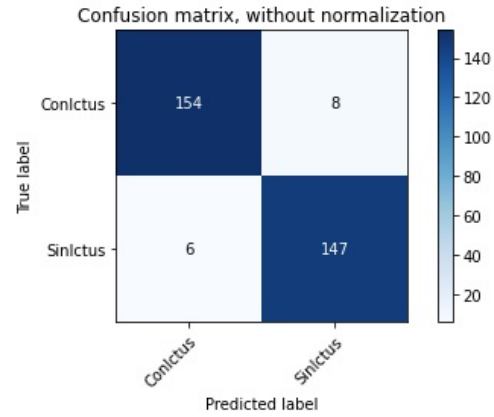
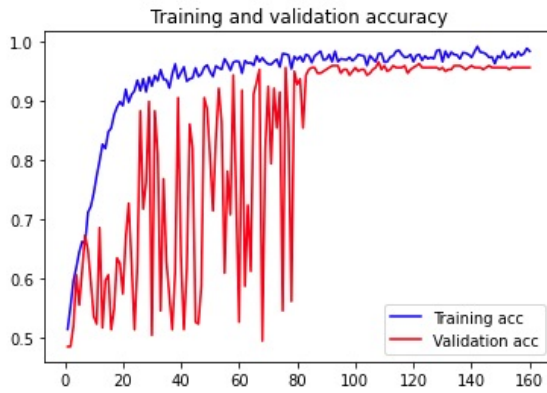


Fig. 3. DenseNet3D 2.2 (top) and ResNet3D 2.0 (bottom) results

learned quite well and is able to make very good predictions in the general case (test). Also, the sensibility is high, at 95%. In the case of the ResNet network, only four tests were done, and the best accuracy (version 2.0, 95%) is not so far from the DenseNet neural network, but it is especially worse in the accuracy obtained in the evaluation/test (79%).

Figures 3a, 3b, 3c and 3d, show the evaluation of the training/testing accuracies of the two best networks DenseNet and ResNet models. It can be seen that the training of the DenseNet network converges faster than that of ResNet and obtains better results.

Therefore, the model chosen is DenseNet 2.2, with the parameters shown in Table I.

## V. CONCLUSIONS AND FUTURE WORKS

In this work, we have proposed the binary classification of NCCT studies in cases with and without stroke. For this purpose, a new dataset has been generated to train several 3D convolutional neural networks. To select the best network, different parameters have been tested, and evaluation metrics have been recorded. The results obtained with the DenseNet3D network have been really good and show that deep learning can be used as a possible assistant for decision-making.

In addition, a new dataset has been generated specifically for stroke detection. The number of cranial CT studies is sufficient to be able to apply transfer learning techniques to perform the classification task. In addition, the DICOM format has been used, a standard used worldwide for the storage and communication of medical images, so that the construction procedure is replicable and extensible to add new case studies and validate the neural network.

Future work aims to expand the number of cases and use higher resolutions for the 3D images. The resolution obtained from the CT scans is higher but has been adapted to the networks used in the study of the paper. Additionally, new deep learning techniques will be applied, such as transforms and/or attention mechanisms. This will allow an improvement in the results obtained with the DenseNet network.

## ACKNOWLEDGMENT

Special thanks to the Hospital Universitario de Navarra for their support in the development of the work and, especially, for allowing the authors to use anonymised patient data.

## REFERENCES

- [1] O. Öman, T. Mäkelä, E. Salli, S. Savolainen, and M. Kangasniemi, "3d convolutional neural networks applied to ct angiography in the detection



- of acute ischemic stroke,” *European radiology experimental*, vol. 3, no. 1, p. 8, 2019.
- [2] M. M. Ramos and T. C. Giadas, “Evaluación vascular en el código ictus: papel de la angio-tomografía computarizada,” *Radiología*, vol. 57, no. 2, pp. 156–166, 2015.
  - [3] P. A. Barber, A. M. Demchuk, J. Zhang, A. M. Buchan, A. S. Group *et al.*, “Validity and reliability of a quantitative computed tomography score in predicting outcome of hyperacute stroke before thrombolytic therapy,” *The Lancet*, vol. 355, no. 9216, pp. 1670–1674, 2000.
  - [4] A. Lisowska, A. O’Neil, V. Dilys, M. Daykin, E. Beveridge, K. Muir, S. McLaughlin, and I. Poole, “Context-aware convolutional neural networks for stroke sign detection in non-contrast ct scans,” in *Annual Conference on Medical Image Understanding and Analysis*. Springer, 2017, pp. 494–505.
  - [5] A. Davis, N. Gordillo, E. Montseny, F. X. Aymerich, M. López-Córdova, J. Mejía, L. Ortega, and B. Mederos, “Automated detection of parenchymal changes of ischemic stroke in non-contrast computer tomography: A fuzzy approach,” *Biomedical Signal Processing and Control*, vol. 45, pp. 117–127, 2018.
  - [6] B. C. Stoel, H. A. Marquering, M. Staring, L. F. Beenen, C. H. Slump, Y. B. Roos, and C. B. Majoie, “Automated brain computed tomographic densitometry of early ischemic changes in acute stroke,” *Journal of medical imaging*, vol. 2, no. 1, p. 014004, 2015.
  - [7] W. S. McCulloch and W. Pitts, “A logical calculus of the ideas immanent in nervous activity,” *The bulletin of mathematical biophysics*, vol. 5, no. 4, pp. 115–133, 1943.
  - [8] Y. LeCun, L. Bottou, Y. Bengio, and P. Haffner, “Gradient-based learning applied to document recognition,” *Proceedings of the IEEE*, vol. 86, no. 11, pp. 2278–2324, 1998.
  - [9] M. I. Razzak, S. Naz, and A. Zaib, “Deep learning for medical image processing: Overview, challenges and the future,” in *Classification in BioApps*. Springer, 2018, pp. 323–350.
  - [10] X. Zhao, L. Liu, S. Qi, Y. Teng, J. Li, and W. Qian, “Agile convolutional neural network for pulmonary nodule classification using ct images,” *International journal of computer assisted radiology and surgery*, vol. 13, no. 4, pp. 585–595, 2018.
  - [11] W. Li, P. Cao, D. Zhao, and J. Wang, “Pulmonary nodule classification with deep convolutional neural networks on computed tomography images,” *Computational and mathematical methods in medicine*, 2016.
  - [12] W. Alakwaa, M. Nassef, and A. Badr, “Lung cancer detection and classification with 3d convolutional neural network (3d-cnn),” *Lung Cancer*, vol. 8, no. 8, p. 409, 2017.
  - [13] Q. Song, L. Zhao, X. Luo, and X. Dou, “Using deep learning for classification of lung nodules on computed tomography images,” *Journal of healthcare engineering*, vol. 2017, 2017.
  - [14] L. Gong, S. Jiang, Z. Yang, G. Zhang, and L. Wang, “Automated pulmonary nodule detection in ct images using 3d deep squeeze-and-excitation networks,” *International journal of computer assisted radiology and surgery*, vol. 14, no. 11, pp. 1969–1979, 2019.
  - [15] F. Liao, M. Liang, Z. Li, X. Hu, and S. Song, “Evaluate the malignancy of pulmonary nodules using the 3-d deep leaky noisy-or network,” *IEEE transactions on neural networks and learning systems*, vol. 30, no. 11, pp. 3484–3495, 2019.
  - [16] L. Gong, S. Jiang, Z. Yang, G. Zhang, and L. Wang, “Automated pulmonary nodule detection in ct images using 3d deep squeeze-and-excitation networks,” *International journal of computer assisted radiology and surgery*, vol. 14, no. 11, pp. 1969–1979, 2019.
  - [17] W. Li, P. Cao, D. Zhao, and J. Wang, “Pulmonary nodule classification with deep convolutional neural networks on computed tomography images,” *Computational and mathematical methods in medicine*, vol. 2016, 2016.
  - [18] R. S. of North America (RSNA). (2021) Rsna-asnr-miccai brats challenge 2021. [Online]. Available: <http://braintumorsegmentation.org/>
  - [19] S. Basheera and M. S. S. Ram, “Classification of brain tumors using deep features extracted using cnn,” in *Journal of Physics: Conference Series*, vol. 1172, no. 1. IOP Publishing, 2019, p. 012016.
  - [20] S. Iqbal, M. U. Ghani, T. Saba, and A. Rehman, “Brain tumor segmentation in multi-spectral mri using convolutional neural networks (cnn),” *Microscopy research and technique*, vol. 81, no. 4, pp. 419–427, 2018.
  - [21] H. Mohsen, E.-S. A. El-Dahshan, E.-S. M. El-Horbaty, and A.-B. M. Salem, “Classification using deep learning neural networks for brain tumors,” *Future Computing and Informatics Journal*, vol. 3, no. 1, pp. 68–71, 2018.
  - [22] C. Yang, A. Rangarajan, and S. Ranka, “Visual explanations from deep 3d convolutional neural networks for alzheimer’s disease classification,” in *AMIA Annual Symposium Proceedings*, vol. 2018. American Medical Informatics Association, 2018, p. 1571.
  - [23] X. W. Gao, R. Hui, and Z. Tian, “Classification of ct brain images based on deep learning networks,” *Computer methods and programs in biomedicine*, vol. 138, pp. 49–56, 2017.
  - [24] A. Khvostikov, K. Aderghal, J. Benois-Pineau, A. Krylov, and G. Catheline, “3d cnn-based classification using smri and md-dti images for alzheimer disease studies,” *arXiv preprint arXiv:1801.05968*, 2018.
  - [25] G. Praveen, A. Agrawal, P. Sundaram, and S. Sardesai, “Ischemic stroke lesion segmentation using stacked sparse autoencoder,” *Computers in biology and medicine*, vol. 99, pp. 38–52, 2018.
  - [26] I. C. on Medical Image Computing and C. A. I. M. 2022. (2022) Ischemic stroke lesion segmentation (isles) 2022. [Online]. Available: <http://www.isles-challenge.org/>
  - [27] C.-M. Lo, P.-H. Hung, and K. L.-C. Hsieh, “Computer-aided detection of hyperacute stroke based on relative radiomic patterns in computed tomography,” *Applied Sciences*, vol. 9, no. 8, p. 1668, 2019.
  - [28] G. Wu, J. Lin, X. Chen, Z. Li, Y. Wang, J. Zhao, and J. Yu, “Early identification of ischemic stroke in noncontrast computed tomography,” *Biomedical Signal Processing and Control*, vol. 52, pp. 41–52, 2019.
  - [29] T. Song, “Generative model-based ischemic stroke lesion segmentation,” *arXiv preprint arXiv:1906.02392*, 2019.
  - [30] N. Takahashi, Y. Shinohara, T. Kinoshita, T. Ohmura, K. Matsubara, Y. Lee, and H. Toyoshima, “Computerized identification of early ischemic changes in acute stroke in noncontrast ct using deep learning,” in *Medical Imaging 2019: Computer-Aided Diagnosis*, vol. 10950. International Society for Optics and Photonics, 2019, p. 109503A.
  - [31] Y. Mokli, J. Pfaff, D. P. Dos Santos, C. Herweh, and S. Nagel, “Computer-aided imaging analysis in acute ischemic stroke—background and clinical applications,” *Neurological research and practice*, vol. 1, no. 1, pp. 1–13, 2019.
  - [32] A. W. Olthof, P. M. van Ooijen, and M. H. R. Mehrizi, “Promises of artificial intelligence in neuroradiology: a systematic technographic review,” *Neuroradiology*, vol. 62, no. 10, pp. 1265–1278, 2020.
  - [33] T. Haifa, B. Jihene, S. Lamia, and B. H. Ahmed, “e-aspects for early detection and diagnosis of ischemic stroke,” in *2020 5th International Conference on Advanced Technologies for Signal and Image Processing (ATSIP)*. IEEE, 2020, pp. 1–5.
  - [34] M. D. Zeiler and R. Fergus, “Visualizing and understanding convolutional networks,” in *European conference on computer vision*. Springer, 2014, pp. 818–833.
  - [35] W. L. Nowinski, J. Walecki, G. Półtorak-Szymczak, K. Sklinda, and B. Mruk, “Ischemic infarct detection, localization, and segmentation in noncontrast ct human brain scans: review of automated methods,” *PeerJ*, vol. 8, p. e10444, 2020.
  - [36] J. Goebel, E. Stenzel, N. Guberina, I. Wanke, M. Koehrmann, C. Kleinschnitz, L. Umutlu, M. Forsting, C. Moeninghoff, and A. Radbruch, “Automated aspect rating: comparison between the frontier aspect score software and the brainomix software,” *Neuroradiology*, vol. 60, no. 12, pp. 1267–1272, 2018.
  - [37] Medical image analysis challenges. [Online]. Available: <https://grand-challenge.org/challenges/>
  - [38] Rsna intracranial hemorrhage detection. [Online]. Available: <https://www.kaggle.com/c/rsna-intracranial-hemorrhage-detection/data>
  - [39] Nema, “Current edition digital imaging and communications in medicine,” *url: https://www.dicomstandard.org/current/1*, 2019, consultado: Agosto 2019.
  - [40] A. Zhang, H. Wang, S. Li, Y. Cui, Z. Liu, G. Yang, and J. Hu, “Transfer learning with deep recurrent neural networks for remaining useful life estimation,” *Applied Sciences*, 2018.